

CASE RECORDS of the MASSACHUSETTS GENERAL HOSPITAL

Founded by Richard C. Cabot  
Eric S. Rosenberg, M.D., *Editor*  
Virginia M. Pierce, M.D., David M. Dudzinski, M.D., Meridale V. Baggett, M.D.,  
Dennis C. Sgroi, M.D., Jo-Anne O. Shepard, M.D., *Associate Editors*  
Kathy M. Tran, M.D., *Case Records Editorial Fellow*  
Emily K. McDonald, Tara Corpuz, *Production Editors*



## Case 17-2020: A 68-Year-Old Man with Covid-19 and Acute Kidney Injury

Meghan E. Sise, M.D., Meridale V. Baggett, M.D., Jo-Anne O. Shepard, M.D.,  
Jacob S. Stevens, M.D., and Eugene P. Rhee, M.D.

### PRESENTATION OF CASE

*Dr. Meridale V. Baggett:* A 68-year-old man was admitted to this hospital with fever, shortness of breath, and acute kidney injury during the pandemic of coronavirus disease 2019 (Covid-19), the disease caused by severe acute respiratory syndrome coronavirus 2 (SARS-CoV-2).

The patient had been in his usual state of health until 4 days before admission, when fever developed, with a temperature of up to 39.9°C and associated shaking chills. He had a poor appetite and was eating and drinking less than usual. Three days before admission, he stopped using long-acting insulin for his diabetes because fasting blood glucose levels were less than 100 mg per deciliter (5.6 mmol per liter; reference range, 70 to 99 mg per deciliter [3.9 to 5.5 mmol per liter]). One day before admission, a dry cough developed. On the morning of admission, the patient noticed shortness of breath. He called his primary care physician, who recommended that he present to the emergency department of this hospital for further evaluation.

In the emergency department, the patient reported ongoing shortness of breath, with no chest pain, orthopnea, or leg swelling. He had not traveled recently. He worked as a limousine driver but had not had known contact with anyone with confirmed SARS-CoV-2 infection.

The patient had a history of diabetes, hypertension, hyperlipidemia, coronary artery disease, obesity, and obstructive sleep apnea. A drug-eluting stent had been placed in the left anterior descending coronary artery 7 years earlier. Medications included aspirin, clopidogrel, dulaglutide, empagliflozin, ezetimibe, glipizide, insulin glargine, lisinopril, metformin, metoprolol, rosuvastatin, and testosterone. There were no known drug allergies. The patient did not smoke, drink alcohol, or use illicit substances. He lived with his girlfriend in a suburb of Boston. His family history included coronary artery disease in his father and emphysema in his mother.

From the Departments of Medicine (M.E.S., M.V.B., E.P.R.) and Radiology (J.-A.O.S.), Massachusetts General Hospital, and the Departments of Medicine (M.E.S., M.V.B., E.P.R.) and Radiology (J.-A.O.S.), Harvard Medical School — both in Boston; and the Department of Medicine, Columbia University Irving Medical Center, and the Department of Medicine, Vagelos College of Physicians and Surgeons — both in New York (J.S.S.).

This case was published on May 13, 2020, at NEJM.org.

DOI: 10.1056/NEJMcpc2002418

Copyright © 2020 Massachusetts Medical Society.

On examination, the temperature was 37.6°C, the blood pressure 157/74 mm Hg, the heart rate 124 beats per minute, the respiratory rate 40 breaths per minute, and the oxygen saturation 94% while the patient was breathing ambient air. The body-mass index (the weight in kilograms divided by the square of the height in meters) was 37.1. The patient had moderately increased work of breathing and diffuse coarse crackles at the lung bases. The mucous membranes were dry. The remainder of the physical examination was normal. The blood creatinine level of 1.3 mg per deciliter (115  $\mu\text{mol}$  per liter; reference range, 0.6 to 1.5 mg per deciliter [53 to 133  $\mu\text{mol}$  per liter]) was higher than the level obtained 1 year earlier (0.8 mg per deciliter [71  $\mu\text{mol}$  per liter]). Other laboratory test results are shown in Table 1.

*Dr. Jo-Anne O. Shepard:* A chest radiograph obtained in the emergency department showed bilateral multifocal patchy opacities, a finding suggestive of pneumonia (Fig. 1A).

*Dr. Baggett:* Blood samples were obtained for culture, and a nasopharyngeal swab was submitted to be tested for SARS-CoV-2 RNA. Two liters of intravenous lactated Ringer's solution were administered, along with ceftriaxone and azithromycin. The patient was admitted to the hospital.

Three hours after admission, the oxygen saturation decreased to 87% while the patient was breathing ambient air and then increased to 92% with the administration of oxygen through a nasal cannula at a rate of 2 liters per minute. Five hours later, shortness of breath increased and the oxygen saturation decreased, and the oxygen flow rate was adjusted to 6 liters per minute. The patient was transferred to the intensive care unit (ICU). Intravenous vancomycin and furosemide were administered. The nucleic acid test for SARS-CoV-2 RNA returned positive. Treatment with hydroxychloroquine was started, and the patient was enrolled in a placebo-controlled clinical trial of remdesivir (ClinicalTrials.gov number, NCT04280705).

Sixteen hours after transfer to the ICU, the patient underwent intubation and mechanical ventilation for persistent tachypnea and worsening oxygen saturation. During the next 24 hours, hypotension developed, with the blood pressure decreasing to 78/45 mm Hg, and treatment with intravenous norepinephrine was initiated. On hospital day 3, the creatinine level increased to 1.8 mg per deciliter (159  $\mu\text{mol}$  per liter), and the

patient's participation in the clinical trial of remdesivir was discontinued. During the next 5 days, his urine output was maintained at 100 ml per hour with the administration of increased doses of intravenous loop diuretics, but the blood urea nitrogen and creatinine levels continued to rise — reaching 111 mg per deciliter (39.6 mmol per liter; reference range, 8 to 25 mg per deciliter [2.9 to 8.9 mmol per liter]) and 6.9 mg per deciliter (610  $\mu\text{mol}$  per liter), respectively — and a mixed metabolic and respiratory acidosis developed. Management decisions were made.

#### DISCUSSION OF PATHOPHYSIOLOGY

*Dr. Meghan E. Sise:* This 68-year-old man who had diabetes, hypertension, hyperlipidemia, coronary artery disease, obesity, and obstructive sleep apnea presented with fever, shortness of breath, and acute kidney injury during the Covid-19 pandemic. Approximately 6% of patients with Covid-19 have a critical illness that is characterized by respiratory failure, shock, or multiorgan dysfunction.<sup>1</sup> Data from China show an incidence of acute kidney injury among hospitalized patients with Covid-19 ranging from 5 to 23%, with acute kidney injury typically manifesting during the second week of infection<sup>2-5</sup>; the incidence in the United States may be higher.

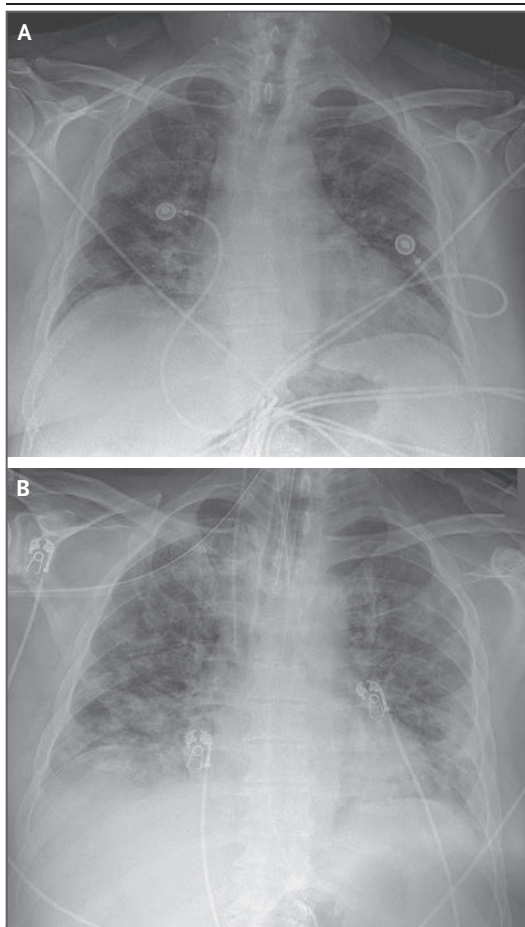
Acute kidney injury — ranging from prerenal azotemia to acute tubular necrosis — may develop in patients with Covid-19 because of poor oral intake, sepsis, and cytokine storm. However, reports from Wuhan, China, have shown high incidences of proteinuria and hematuria by dipstick testing, findings that were seen in this patient.<sup>4,6</sup> Because angiotensin-converting enzyme 2 (ACE2), a putative receptor for SARS-CoV-2, is expressed in kidneys in humans, the kidneys may be a direct target of the virus.<sup>7-9</sup> In some studies, the viral RNA has been recovered in urine.<sup>10-13</sup> Histopathological analysis of kidney tissue from patients with Covid-19 has been limited to autopsies.

A report describing autopsy findings in 6 patients who had died from Covid-19 in Wuhan, China, indicated that severe acute tubular necrosis was observed on light microscopic examination in all 6 patients, and moderate-to-severe lymphocytic infiltration was observed in 5.<sup>3</sup> Kidney tissue from all 6 patients had positive immunohistochemical staining for the nucleocapsid

<b>Table 1. Laboratory Data.*</b>				
<b>Variable</b>	<b>Reference Range, Adults†</b>	<b>On Admission</b>	<b>Hospital Day 9</b>	<b>Hospital Day 15</b>
<b>Blood</b>				
Hematocrit (%)	36–46	39.8	27.9	26.3
Hemoglobin (g/dl)	12–16	12.4	8.6	8.0
White cells (per $\mu$ l)	4500–11,000	10,710	12,430	11,540
Differential count (per $\mu$ l)				
Neutrophils	1800–7700	9600	9160	9090
Lymphocytes	1000–4800	660	1390	1340
Monocytes	200–1200	340	1300	810
Eosinophils	0–900	10	360	230
Platelets	150,000–400,000	304,000	403,000	307,000
Prothrombin time (sec)	11.5–14.5	15.2	16.4	15.4
Prothrombin-time international normalized ratio	0.9–1.1	1.2	1.3	1.2
Activated partial-thromboplastin time (sec)	22–35	NA	36.3	27.5
Sodium (mmol/liter)	135–145	134	143	148
Potassium (mmol/liter)	3.4–4.8	5.4	3.8	3.9
Chloride (mmol/liter)	100–108	96	101	111
Carbon dioxide (mmol/liter)	23.0–31.9	17	16	19
Urea nitrogen (mg/dl)	8–25	17	111	109
Creatinine (mg/dl)	0.6–1.5	1.3	6.9	3.6
Glucose (mg/dl)	70–110	234	159	273
D-dimer (ng/ml)	<500	1515	8322	5666
Ferritin ( $\mu$ g/liter)	20–300	367	434	280
Lactate dehydrogenase (U/liter)	110–210	482	354	306
C-reactive protein (mg/liter)	<8	397.5	136.6	41.0
Creatine kinase (U/liter)	60–400	184	57	135
<b>Urine</b>				
Bilirubin	Negative	Negative	Negative	Negative
Blood	Negative	2+	1+	2+
Clarity	Clear	Turbid	Turbid	Turbid
Glucose	Negative	3+	1+	Negative
Ketones	Negative	2+	Negative	Negative
pH	5–9	5.5	5.0	5.0
Protein	Negative	2+	1+	1+
Specific gravity	1.001–1.035	1.020	1.014	1.016
Red cells (per high-power field)	0–2	None	5–10	0–2
White cells (per high-power field)	<10	<10	<10	<10

\* To convert the values for urea nitrogen to millimoles per liter, multiply by 0.357. To convert the values for creatinine to micromoles per liter, multiply by 88.4. To convert the values for glucose to millimoles per liter, multiply by 0.05551. NA denotes not available.

† Reference values are affected by many variables, including the patient population and the laboratory methods used. The ranges used at Massachusetts General Hospital are for adults who are not pregnant and do not have medical conditions that could affect the results. They may therefore not be appropriate for all patients.



**Figure 1. Chest Radiographs.**

A chest radiograph obtained on admission (Panel A) shows bilateral multifocal patchy opacities, a finding suggestive of pneumonia. A chest radiograph obtained 1 day before continuous venovenous hemofiltration was initiated (Panel B) shows evidence of an increase in bilateral consolidation and interstitial opacities, a finding suggestive of worsening pulmonary edema, pneumonia, or acute respiratory distress syndrome. Also shown are an endotracheal tube in the trachea, a catheter in the superior vena cava, and a nasogastric tube in place.

protein antigen in the renal tubular epithelium, and each patient had membrane attack complex (terminal component of complement) deposited on the renal tubular epithelium. A series describing autopsy findings in 26 patients who had died from Covid-19 also showed severe acute tubular necrosis; in addition, obstruction of peritubular capillary lumens and glomerular capillary loops with erythrocytes was seen in several cases.<sup>14</sup> Although these autopsy series describe the most severely affected patients, these findings

suggest it is possible that direct viral cytotoxicity, immunologic injury, and perhaps even microthrombi and thrombotic microangiopathy contribute to the pathogenesis of acute kidney injury in patients with Covid-19, leading to injury above and beyond the systemic hemodynamic and inflammatory effects.

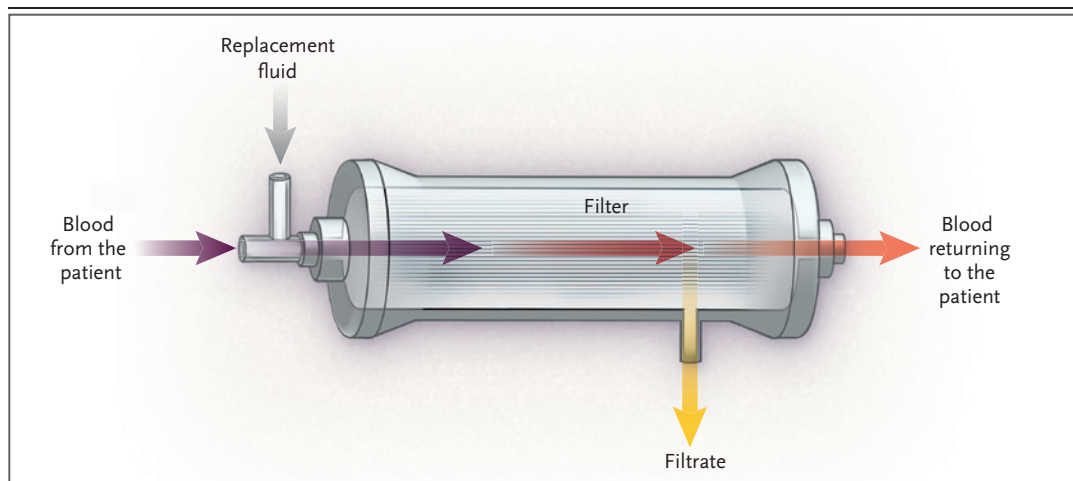
#### DISCUSSION OF MANAGEMENT

*Dr. Eugene P. Rhee:* The development of acute kidney injury in this patient with Covid-19 requires specific management considerations. These include maintaining an adequate mean arterial pressure for organ perfusion, adjusting medication doses as needed because of the reduced estimated glomerular filtration rate, and assessing volume status.

#### ASSESSMENT AND MANAGEMENT OF VOLUME STATUS

It is important to consider volume status, although the appropriate management approach in patients with Covid-19 is unclear. In extrapolating from existing knowledge about acute respiratory distress syndrome in other contexts,<sup>15</sup> it appears that a conservative approach to fluid resuscitation and efforts to avoid hypervolemia would be appropriate. Intravenous medications should be concentrated if possible, and in patients with oliguric acute kidney injury, augmentation of urine output with diuretics may be needed. Doses of loop diuretics may need to be increased or administered as a continuous infusion if clinically significant hypoalbuminemia — an important cause of diuretic resistance — develops as a result of systemic inflammation.

Although diuresis may be a key component in the treatment of patients with Covid-19, overdiuresis has the potential to exacerbate kidney injury, and several features of this infection may magnify this risk. First, patients may present with clinically significant volume contraction due to poor oral intake, insensible fluid loss associated with fever, or diarrhea that had preceded admission for several days. Second, some patients receive minimal fluid resuscitation at the time of initial treatment because of concern about the risk of rapid respiratory decompensation. Third, the use of a strategy involving a high positive end-expiratory pressure may further reduce venous return. Fourth, prolonged ventilator dependence extends the window in which ongoing



**Figure 2. Considerations for Continuous Venovenous Hemofiltration in Patients with Covid-19.**

Shown is a simplified overview of continuous venovenous hemofiltration, a common form of continuous renal replacement therapy. Blood from the patient is filtered through a permeable membrane (the filter) and the filtrate is discarded, resulting in clearance of urea nitrogen, creatinine, potassium, phosphate, and other substances; cells and larger proteins such as albumin are not filtered. Replacement fluid that is isotonic to plasma is provided to replace volume and provide base equivalents, typically in the form of bicarbonate or less commonly citrate. Although it reduces clearance efficiency, replacement fluid is usually provided prefilter rather than postfilter in order to prevent hemoconcentration and subsequent clotting in the filter. Citrate-based replacement fluid can provide additional anticoagulation by chelating calcium in the filter; the patient must have adequate hepatic function to metabolize citrate into bicarbonate. Other common approaches to attenuate filter clotting include increasing the blood flow rate, which can be limited by the quality of vascular access, and infusing an anticoagulant, either prefilter or systemically. Increasing the rate of replacement fluid and filtrate turnover increases the treatment dose and is one approach to maximizing clearance for intermittent therapy, which may be indicated if continuous therapy is precluded by recurrent clotting or because a machine is to be shared among multiple patients.

diuresis can worsen acute kidney injury. Finally, among patients with Covid-19, chest imaging studies may show peripheral lung opacities without radiographically significant alveolar edema; it is possible that the beneficial effect of diuresis on pulmonary function may be attenuated in this context.

The initial management of kidney injury in this patient included the administration of intermittent doses of intravenous furosemide to maintain an approximately even fluid balance, on the basis of recorded inputs and outputs. However, his central venous pressure ranged from 4 to 8 mm Hg, and he probably had a net negative fluid balance in the context of persistent fever.

#### RENAL REPLACEMENT THERAPY

Because the patient had progressive azotemia, mixed metabolic and respiratory acidosis, and increased diffuse interstitial and airspace opacities on a chest radiograph (Fig. 1B), a dialysis catheter was placed in the left internal jugular vein on hospital day 9, with the plan to initiate

renal replacement therapy. Given that he was receiving vasopressor support, continuous renal replacement therapy (CRRT) with continuous venovenous hemofiltration was initiated (Fig. 2). However, sustained therapy was limited by recurrent clotting within the CRRT filter, a problem that has been widely noted in patients with Covid-19. Attempts to perform CRRT in this patient were further confounded by the inability to maintain adequate blood flow through the dialysis catheter, which was attributed to both clotting within the catheter and vessel collapse around the catheter in the context of reduced intravascular volume. Even after the patient received modest volume repletion and a new dialysis catheter was placed in the right internal jugular vein, filter clotting and catheter malfunction persisted, resulting in reduced treatment time, the need to discard several filters, and worsening of anemia owing to the loss of extracorporeal blood in malfunctioning CRRT circuits. Strategies that were used to decrease clotting during CRRT — including prefilter in-



fusion of unfractionated heparin and the use of a citrate-based replacement fluid — were also unsuccessful in preventing filter clotting (Fig. 2).

Given the frequent interruptions in treatment, CRRT at a high dose (i.e., with a high rate of replacement fluid turnover) was to be administered whenever the CRRT circuit was patent. Although high-dose CRRT has not been shown to confer a benefit over standard-dose CRRT,<sup>16,17</sup> high-dose CRRT may be a reasonable approach in patients with Covid-19 to compensate for the anticipated loss of clearance time due to filter clotting. It can also compensate for the loss of clearance time that occurs when the patient is placed in the prone position (which can impair the function of some dialysis catheters) or when a single CRRT machine needs to be used for more than one patient. High-dose CRRT is not a practical approach if there is a limited supply of replacement fluid.

After 3 days of interrupted therapy, CRRT was discontinued. By that time, the patient had been weaned off vasopressors, his oxygenation was improving, and his urine output was increasing spontaneously. However, his mental status remained poor despite the absence of sedation medications, and the blood urea nitrogen level had steadily increased to 108 mg per deciliter (38.6 mmol per liter).

On hospital day 15, standard hemodialysis was initiated. Unfractionated heparin was used to prime the dialysis machine, and then heparin was flushed through the dialysis filter several times during the 3.5-hour treatment. The patient had subsequent normalization of the blood sodium and bicarbonate levels and a substantial decrease in the blood urea nitrogen level. Several of his hematologic and inflammatory abnormalities started to abate (Table 1). It is unclear whether the success of hemodialysis, as compared with CRRT, was related to the method (i.e., the shorter duration of treatment with aggressive heparin flushes) or to an improvement in the patient's underlying condition.

#### TREATMENT OF COVID-19 IN PATIENTS WITH KIDNEY INJURY

*Dr. Sise:* In this patient, CRRT and hemodialysis are supportive therapies that do not directly address the underlying disease. Currently, no therapies have proved to be effective for patients with Covid-19. As of May 1, 2020, the Food and Drug Administration has issued an Emergency

Use Authorization to permit the use of remdesivir for the treatment of suspected or laboratory-confirmed Covid-19 in adults and children who are hospitalized with severe disease. Several clinical trials of remdesivir and other investigational approaches are still ongoing; however, many patients with acute or chronic kidney disease do not meet eligibility criteria for participation in clinical trials.

#### *Remdesivir*

Because SARS-CoV-2 uses an RNA-dependent RNA polymerase for replication of its genome, agents that target this enzyme may be effective. Remdesivir, which was originally developed to treat Ebola virus disease and has been studied for the treatment of SARS and Middle East respiratory syndrome (MERS), can inhibit SARS-CoV-2 in vitro.<sup>18,19</sup> A recent uncontrolled trial suggested possible clinical benefit.<sup>20</sup> Remdesivir is currently being studied in multiple phase 3 clinical trials. It was approved for emergency use after review of the top-line data from a randomized, double-blind, placebo-controlled trial (NCT04280705) and from an open-label trial that evaluated different durations of remdesivir treatment (NCT04292899); the full results of each have not yet been published.

Unfortunately, many patients with severe acute kidney injury are not eligible for these studies or are required to discontinue participation (as in this case) because remdesivir is eliminated renally and also because of concern about accumulation of the sulfobutylether- $\beta$ -cyclodextrin carrier used in the formulation of remdesivir.<sup>21</sup> Thus, there is an urgent need for reporting of outcomes associated with the compassionate use of remdesivir in patients with Covid-19 and acute or chronic kidney disease.

#### *Favipiravir*

Favipiravir, which is another broad-spectrum antiviral agent that inhibits RNA-dependent RNA polymerase, has been approved for the treatment of influenza in Japan and is currently being studied in multiple clinical trials across the United States and internationally. Available data from patients with Covid-19 are limited, and results regarding efficacy have been mixed.<sup>22,23</sup> Favipiravir can be administered orally with excellent bioavailability and is excreted in the urine. In patients with mild-to-moderate renal insufficiency, the maximum concentration of the

active metabolite of favipiravir is approximately 2 times as high as the level observed in patients with normal kidney function<sup>24</sup>; however, since adverse events are not worse in patients with mild-to-moderate renal insufficiency, dose adjustments are not recommended. Favipiravir has not been studied in patients with severe renal insufficiency (an estimated glomerular filtration rate of <20 ml per minute per 1.73 m<sup>2</sup> of body-surface area), and these patients are being excluded from current clinical trials of favipiravir.

#### *Hydroxychloroquine and Chloroquine*

Several medications that are commonly used for the treatment of other medical conditions have been suggested as possible therapies for Covid-19. Such medications include hydroxychloroquine and chloroquine, both of which inhibit SARS-CoV-2 in vitro.<sup>19,25-27</sup> However, there are limited clinical data regarding the efficacy of these drugs for the treatment of Covid-19, and these data show conflicting results.<sup>28-31</sup> Hydroxychloroquine can be used in patients with acute kidney injury without dose adjustment; however, the drug concentration in the blood is likely to be increased, given that kidney excretion accounts for 15 to 25% of clearance.<sup>32</sup> Patients with acute kidney injury who receive these drugs should be monitored for QT prolongation, since electrolyte abnormalities that occur in patients with acute kidney injury may increase the risk of cardiac arrhythmia.

#### *Antiinflammatory Medications*

Patients with severe Covid-19 often have a very high inflammatory response, clinical features that mimic cytokine release syndrome, and elevated interleukin-6 levels; thus, antiinflammatory therapies that target the interleukin-6 pathway are under investigation. Since these agents are monoclonal antibodies, dose adjustment should not be needed for patients with acute kidney injury. Tocilizumab, a humanized monoclonal antibody to the interleukin-6 receptor, has been used in patients with acute kidney injury resulting from cytokine release syndrome after chimeric antigen receptor T-cell therapy.<sup>33</sup>

#### *Anticoagulation*

Among patients with Covid-19, there are increased incidences of venous thromboembolic events<sup>34</sup> and disseminated intravascular coagulation, both of which are associated with poor

outcomes.<sup>35,36</sup> Empirical systemic anticoagulation is being considered for some patients with severe Covid-19, particularly those with a D-dimer level of more than 6 times the upper limit of the normal range.<sup>37</sup> At our center currently, systemic anticoagulation is generally reserved for patients with overt thromboembolic events or other indications for anticoagulation, such as atrial fibrillation. However, because of the frequency of clotting in CRRT filters and catheters, as seen in this patient, we are increasingly using systemic anticoagulation in patients who are receiving CRRT as we await more data and evidence-based guidelines.

Whether antiviral, antiinflammatory, or anticoagulant treatment strategies can decrease the incidence or severity of acute kidney injury in patients with Covid-19 is unknown.

#### **CREATING SURGE CAPACITY IN NEPHROLOGY**

*Dr. Jacob S. Stevens:* Although we can take lessons from responses to natural disasters such as Hurricanes Sandy and Katrina, the U.S. health care system has never experienced a surge in demand for renal replacement therapies as extreme as the one we are now facing during the Covid-19 pandemic. Throughout New York City, where the mismatch between need and availability has been considerable, our response has required a close evaluation of our clinical procedures. We have been forced to examine every aspect of our renal replacement therapy program, which has included taking a careful inventory of working machines, catheters, and therapy fluids, as well as taking account of all physicians, ICU nurses, and hemodialysis nurses and technicians. As surge capacity plans have been developed by hospital leadership, we have participated in walk-throughs of new spaces to assess whether the physical environment would be compatible with different renal replacement therapies — for example, whether adequate water pressure could be supplied and appropriate drainage would be available for the elimination of dialysis effluent. We have also coordinated closely with other hospitals in our health care system to institute protocols for sharing CRRT machines so that we can respond in real time to patient needs throughout New York City.

In addition to requiring creative use of space and existing CRRT machines, our response has required close attention to conservation measures. At our institution, daily virtual huddles

have allowed us to identify the least sick of our critically ill patients, who would have the best chance of successfully making the transition from CRRT to hemodialysis or transitional therapies, which can be conceptualized as CRRT performed intermittently with higher rates of blood flow and therapy fluid turnover. As noted previously, the use of CRRT machines with such prescriptions can allow for more than one patient to receive therapy from a single machine (e.g., with each patient having 1 day “on” therapy and 1 day “off” therapy, as clinically possible). In parallel, we have aligned our clinical service models with specific geographic locations to facilitate coordination of movement of machines among patients.

Sharing of machines can maximize the number of patients who are able to receive therapy, but it does not address the potential shortage of therapy fluid (dialysate for dialytic methods and replacement fluid for convective methods) and other consumables. The frequent clotting observed in patients with Covid-19, as highlighted by this case, has substantially increased the use of CRRT filters. Collaboration with critical care pharmacists to explore in-house compounding of therapy fluid is crucial, but this strategy may not always be feasible, given the volume needed to support a large CRRT program. Clinicians may need to adapt to projected shortages by reducing prescriptions for therapy fluid to below standard doses as a temporizing measure until supply stocks are replenished. A complementary approach would be to prescribe CRRT according to the number of therapy fluid bags needed per patient per day, rather than prescribing a set rate and duration, to minimize the need to discard partially used bags when sharing machines. These alternative prescriptions, which are subject to frequent modifications, need to be explained to other caregivers, since they affect hemodynamics, metabolic and volume control, and dosing of medications such as antimicrobial therapy.

This pandemic has catalyzed adaptive interactions throughout our institution. For example, cross-training cardiopulmonary bypass and extracorporeal membrane oxygenation perfusionists to perform CRRT, with ICU nurses in a supervisory role, has facilitated rapid expansion of the capacity for CRRT beyond our traditional staff-

ing models. The closure of operating rooms for nonemergency surgeries has facilitated a natural partnership with our surgical colleagues, who have made their services available around the clock to perform vascular-access procedures for patients requiring renal replacement therapy. Furthermore, surgeons and interventional radiologists have been placing catheters to permit peritoneal dialysis, an additional option for renal replacement therapy that we have used as an adjunct to our CRRT and hemodialysis programs in select cases to increase capacity. Local circumstances will require different solutions, but a multifaceted and collaborative approach is clearly essential to maximize the number of patients who receive lifesaving renal replacement therapies.

---

#### FOLLOW-UP

---

*Dr. Rhee:* On hospital day 16, when this patient was able to follow simple commands, he was extubated. He was transferred out of the ICU on hospital day 17. Two days later, he became increasingly tachypneic, and his respiratory rate increased from 26 to 40 breaths per minute. Duplex ultrasonography revealed a nonocclusive deep-vein thrombosis of the proximal and mid-superficial right femoral vein. Additional imaging studies to rule out pulmonary embolism were deferred because of underlying chest abnormalities and the need to limit exposure to intravenous contrast material in the context of acute kidney injury. We administered unfractionated heparin as empirical therapy for pulmonary embolism. The patient recovered well; he did not receive any additional hemodialysis treatments and had gradual improvement in kidney function. After 31 days in the hospital, he was transferred to a rehabilitation facility.

---

#### CONCLUSION

---

*Dr. Rhee:* For the nephrologist, the Covid-19 pandemic raises many questions about pathophysiology, prognosis, and treatment. However, in observing patients with Covid-19 and severe acute kidney injury leading to renal replacement therapy, I am struck by the cohesion with old themes dating back to the inception of dialysis, including the specific challenges of maintaining patent circulatory access and anticoagulation, as



well as the question of how to allocate care if there are limited resources.

Given the massive strain on existing resources, renal replacement therapy has the potential to once again be limited. This poses a challenge that requires technical and logistic adjustments, as well as consideration of fundamental questions about fairness and justice. For example, because acute kidney injury, end-stage renal disease, and their risk factors disproportionately affect racial and ethnic minorities, using these diagnoses as exclusion criteria for resource allocation carries the risk of magnifying existing health inequities. In managing the burden of acute kidney injury among hospitalized patients

with Covid-19, we acknowledge the considerable challenges — physical, emotional, and even moral — that nephrologists, nephrology nurses, and colleagues have confronted and will continue to confront.

#### FINAL DIAGNOSIS

Acute kidney injury in the context of severe acute respiratory syndrome coronavirus 2 (SARS-CoV-2) infection.

Disclosure forms provided by the authors are available with the full text of this article at NEJM.org.

We thank Dr. Merranda Logan for assistance in the preparation of an earlier version of the manuscript, and Drs. Ali Gharavi and Jai Radhakrishnan for their review.

#### REFERENCES

- World Health Organization. Report of the WHO-China Joint Mission on Coronavirus Disease 2019 (COVID-19). February 28, 2020 ([https://www.who.int/publications-detail/report-of-the-who-china-joint-mission-on-coronavirus-disease-2019-\(covid-19\)](https://www.who.int/publications-detail/report-of-the-who-china-joint-mission-on-coronavirus-disease-2019-(covid-19))).
- Zhou F, Yu T, Du R, et al. Clinical course and risk factors for mortality of adult inpatients with COVID-19 in Wuhan, China: a retrospective cohort study. *Lancet* 2020;395:1054-62.
- Diao B, Wang C, Wang R, et al. Human kidney is a target for novel severe acute respiratory syndrome coronavirus 2 (SARS-CoV-2) infection. *medRxiv*. 2020 (<https://www.medrxiv.org/content/10.1101/2020.03.04.20031120v4>) (preprint).
- Cheng Y, Luo R, Wang K, et al. Kidney disease is associated with in-hospital death of patients with COVID-19. *Kidney Int* 2020;97:829-38.
- Li Z, Wu M, Yao J, et al. Caution on kidney dysfunctions of Covid-19 patients. *medRxiv*. 2020 (<https://www.medrxiv.org/content/10.1101/2020.02.08.20021212v2>) (preprint).
- Cao M, Zhang D, Wang Y, et al. Clinical features of patients infected with the 2019 novel coronavirus (COVID-19) in Shanghai, China. *medRxiv*. 2020 (<https://www.medrxiv.org/content/10.1101/2020.03.04.20030395v1>) (preprint).
- Lely AT, Hamming I, van Goor H, Navis GJ. Renal ACE2 expression in human kidney disease. *J Pathol* 2004;204:587-93.
- Lin W, Hu L, Zhang Y, et al. Single-cell analysis of ACE2 expression in human kidneys and bladders reveals a potential route of 2019-nCoV infection. *bioRxiv*. 2020 (<https://www.biorxiv.org/content/10.1101/2020.02.08.939892v1>) (preprint).
- Fan C, Li K, Ding Y, Lu WL, Wang J. ACE2 expression in kidney and testis may cause kidney and testis damage after 2019-nCoV infection. *medRxiv*. 2020 (<https://www.medrxiv.org/content/10.1101/2020.02.12.20022418v1>) (preprint).
- Wang W, Xu Y, Gao R, et al. Detection of SARS-CoV-2 in different types of clinical specimens. *JAMA* 2020 March 11 (Epub ahead of print).
- Peng L, Liu J, Xu W, et al. 2019 Novel coronavirus can be detected in urine, blood, anal swabs and oropharyngeal swabs samples. *medRxiv*. 2020 (<https://www.medrxiv.org/content/10.1101/2020.02.21.20026179v1>) (preprint).
- To KK-W, Tsang OT-Y, Leung W-S, et al. Temporal profiles of viral load in posterior oropharyngeal saliva samples and serum antibody responses during infection by SARS-CoV-2: an observational cohort study. *Lancet Infect Dis* 2020 March 23 (Epub ahead of print).
- Chen Y, Chen L, Deng Q, et al. The presence of SARS-CoV-2 RNA in the feces of COVID-19 patients. *J Med Virol* 2020 April 3 (Epub ahead of print).
- Su H, Yang M, Wan C, et al. Renal histopathological analysis of 26 postmortem findings of patients with COVID-19 in China. *Kidney International*. 2020 ([https://www.kidney-international.org/article/S0085-2538\(20\)30369-0/abstract](https://www.kidney-international.org/article/S0085-2538(20)30369-0/abstract)).
- The National Heart, Lung, and Blood Institute Acute Respiratory Distress Syndrome (ARDS) Clinical Trials Network. Comparison of two fluid-management strategies in acute lung injury. *N Engl J Med* 2006;354:2564-75.
- The RENAL Replacement Therapy Study Investigators. Intensity of continuous renal-replacement therapy in critically ill patients. *N Engl J Med* 2009;361:1627-38.
- The VA/NIH Acute Renal Failure Trial Network. Intensity of renal support in critically ill patients with acute kidney injury. *N Engl J Med* 2008;359:7-20.
- Sheahan TP, Sims AC, Graham RL, et al. Broad-spectrum antiviral GS-5734 inhibits both epidemic and zoonotic coronaviruses. *Sci Transl Med* 2017;9:eaa13653.
- Wang M, Cao R, Zhang L, et al. Remdesivir and chloroquine effectively inhibit the recently emerged novel coronavirus (2019-nCoV) in vitro. *Cell Res* 2020;30:269-71.
- Grein J, Ohmagari N, Shin D, et al. Compassionate use of remdesivir for patients with severe Covid-19. *N Engl J Med*. DOI: 10.1056/NEJMoa2007016.
- Holshue ML, DeBolt C, Lindquist S, et al. First case of 2019 novel coronavirus in the United States. *N Engl J Med* 2020; 382:929-36.
- Cai Q, Yang M, Liu D, et al. Experimental treatment with favipiravir for COVID-19: an open-label control study. *Engineering (Beijing)* 2020 March 18 (Epub ahead of print).
- Chen C, Zhang Y, Huang J, et al. Favipiravir versus arbidol for COVID-19: a randomized clinical trial. *medRxiv*. 2020 (<https://www.medrxiv.org/content/10.1101/2020.03.17.20037432v4>) (preprint).
- Pharmaceuticals and Medical Devices Agency. Report on the deliberation results — favipiravir. March 4, 2014 (<https://www.pmda.go.jp/files/000210319.pdf>).
- Yao X, Ye F, Zhang M, et al. In vitro antiviral activity and projection of optimized dosing design of hydroxychloroquine for the treatment of severe acute respiratory syndrome coronavirus 2 (SARS-CoV-2). *Clin Infect Dis* 2020 March 9 (Epub ahead of print).
- Liu J, Cao R, Xu M, et al. Hydroxychloroquine, a less toxic derivative of chloroquine, is effective in inhibiting SARS-CoV-2 infection in vitro. *Cell Discov* 2020;6:16.
- Biot C, Daher W, Chavain N, et al. Design and synthesis of hydroxyferroquine

- derivatives with antimalarial and antiviral activities. *J Med Chem* 2006;49:2845-9.
28. Gautret P, Lagier J-C, Parola P, et al. Hydroxychloroquine and azithromycin as a treatment of COVID-19: results of an open-label non-randomized clinical trial. *Int J Antimicrob Agents* 2020 March 20 (Epub ahead of print).
29. Molina JM, Delaugerre C, Le Goff J, et al. No evidence of rapid antiviral clearance or clinical benefit with the combination of hydroxychloroquine and azithromycin in patients with severe COVID-19 infection. *Med Mal Infect* 2020 March 30 (Epub ahead of print).
30. Chen J, Liu D, Liu L, et al. A pilot study of hydroxychloroquine in treatment of patients with moderate COVID-19. *J Zhejiang Univ (Med Sci)* 2020;49(2).
31. Department of Science and Technology of Guangdong Province, Health Commission of Guangdong Province. Expert consensus on chloroquine phosphate for the treatment of novel coronavirus pneumonia. *Zhonghua Jie He He Hu Xi Za Zhi* 2020;43:185-8. (In Chinese.)
32. Tett SE. Clinical pharmacokinetics of slow-acting antirheumatic drugs. *Clin Pharmacokinet* 1993;25:392-407.
33. Gupta S, Seethapathy H, Stroehbein IA, et al. Acute kidney injury and electrolyte abnormalities after chimeric antigen receptor T-cell (CAR-T) therapy for diffuse large B-cell lymphoma. *Am J Kidney Dis* 2020 January 20 (Epub ahead of print).
34. Xie Y, Wang X, Yang P, Zhang S. COVID-19 complicated by acute pulmonary embolism. *Radiol Cardiothorac Imaging* 2020;2(2):e200067 (<https://pubs.rsna.org/doi/pdf/10.1148/ryct.2020200067>).
35. Guan W, Ni Z, Hu Y, et al. Clinical characteristics of coronavirus disease 2019 in China. *N Engl J Med* 2020;382:1708-20.
36. Tang N, Li D, Wang X, Sun Z. Abnormal coagulation parameters are associated with poor prognosis in patients with novel coronavirus pneumonia. *J Thromb Haemost* 2020;18:844-7.
37. Tang N, Bai H, Chen X, Gong J, Li D, Sun Z. Anticoagulant treatment is associated with decreased mortality in severe coronavirus disease 2019 patients with coagulopathy. *J Thromb Haemost* 2020 March 27 (Epub ahead of print).

Copyright © 2020 Massachusetts Medical Society.