

Clinical remission of a critically ill COVID-19 patient treated by human umbilical cord mesenchymal stem cells

Bing Liang^{1,#}, Junhui Chen^{2,#}, Tao Li^{3,#}, Haiying Wu^{4,#}, Wenjie Yang^{1,#}, Yanjiao Li⁵, Jianchun Li¹, Congtao Yu², Fangang Nie¹, Zhaoxia Ma⁵, Mingxi Yang¹, Panrong Nie⁶, Yanfeng Gao^{2,7,*},
Chuanyun Qian^{4,*}, Min Hu^{2,5,8,*}

¹ Department of Critical Care Medicine, Baoshan People's Hospital, Baoshan 678000, China

² Intervention and Cell Therapy Center, Peking University Shenzhen Hospital, Shenzhen 518035, China

³ Yunnan Yasheng Medical Technology Co., Ltd., Kunming 650021, China

⁴ Emergency Department of the First Affiliated Hospital of Kunming Medical University, EICU/MICU, Kunming 650032, China

⁵ Yunnan Key Laboratory for Basic Research on Bone and Joint Diseases & Yunnan Stem Cell Translational Research Center, Kunming University, Kunming 650214, China

⁶ Department of Neonatology, Baoshan People's Hospital, Baoshan, 678000, China

⁷ School of Pharmaceutical Sciences (Shenzhen), Sun Yat-sen University, Shenzhen 517108, China

⁸ Yunnan Jici Institute for Regenerative Medicine co., Ltd., Kunming 650106, China

These authors contribute equally.

* Correspondence to: E-mail: huminyнкm@163.com (Hu M.); qianchuanyun@126.com (Qian C.); yfgao@hotmail.com (Gao Y.)

Abstract

Background

The COVID-19 cases increased very fast in the last two months. The mortality among critically ill patients, especially the elder ones, was relatively high. Considering that most of the dead patients were caused by severe inflammation response, it is very urgent to develop effective therapeutic agents and strategies for these patients. The human umbilical cord mesenchymal stem cells (hUCMSCs) have shown very good capability to modulate immune response and repair the injured tissue with good safety.

Case Presentation

Here, we reported the treatment process and clinical outcome of a 65-year-old female critically ill COVID-19 patient infected with 2019-nCoV (now called SARS-CoV-2). The significant clinical outcome and well tolerance was observed by the adoptive transfer of allogenic hUCMSCs.

Conclusions

Our results suggested that the adoptive transfer therapy of hUCMSCs might be an ideal choice to be used or combined with other immune modulating agents to treat the critically ill COVID-19 patients.

Keyword: COVID-19; 2019 novel coronavirus, critically ill, mesenchymal stem cell

Background

In December 2019, the outbreak of 2019 novel coronavirus (now called SARS-CoV-2) infected pneumonia (COVID-19) began in Wuhan, China. As of 22th Feb. 2020, 2019 novel coronavirus had infected 76392 people in China (among which 2348 were killed) and 1404 people in other twenty-seven countries and regions (among which twelve people were killed) [1]. It was reported that the elder patients were inclined to get more severe symptom, and the ICU admission ratio of them was significantly than the younger. Including the ground glass opacity in the lung, the other typical diagnosis characteristic of the critically ill patients was significant decrease in lymphocytes along with the increase of neutrophils. The ICU admission patients have higher concentrations of IL-6, G-CSF, IP10, MCP-1, MIP1A, and TNF- α , indication the occurrence of cytokine storm [2, 3]. Persistence of cytokine storm will thus cause the severe organ injury and death [4]. There are no good choice to overcome the cytokine storm, these critically ill patients were always treated with glucocorticoid. But in most cases, the treatment of glucocorticoid will cause severe side effects including osteoporosis and hypoimmunity, or even delay the clearance of the virus [2, 5]. Therefore, it is very urgent to discover novel strategies to treat these critically ill patients [6].

Mesenchymal stem cells (MSCs) have been widely used to treat type 2 diabetes, autoimmune disease, spinal cord injury, GVHD, and other diseases with very good safety [7, 8]. Among which, the umbilical cord mesenchymal stem cells (hUCMSCs) can be easily get and cultured. hUCMSCs have shown very significant immunomodulation and tissue repair effects with low immunogenicity, which makes them very ideal candidate to the allogenic adoptive transfer therapy. It was also suggested to be potential to treat the H5N1 infection induced acute lung injury, which showed similar inflammatory cytokine profile to that of COVID-19 [9]. Up to now, the therapeutic effects of MSCs on COVID-19 have not been reported yet.

Here, we will introduce a critically ill elder female patient in China infected with 2019 novel coronavirus. The characteristics of the vital signs, CT images, clinical laboratory profiles, and major immune cell changes will be investigated. The clinical outcome of hUCMSCs adoptive transfer therapy will be also discussed.

Case Presentation

On January 27, 2020, a 65-year-old woman felt fatigue and fever with a body temperature of 38.2°C, then cough with small amount of white bubble sputum. Considering that she had flown from Wuhan on January 21, 2020, she was immediately sent to the Longling People's Hospital, and the throat swabs were collected. Then, antibiotics and phlegm reducing drugs were given for supportive treatment. On January 28, she had chest tightness with SPO₂ of 81%, and blood pressure 160/91 mmHg. On the same day, the real-time RT-PCR result reported 2019 novel coronavirus positive, and X-ray examination showed ground glass opacity in the right lung. IFN- α inhalation treatment was performed. On January 29 morning, she felt chest tightness and more difficult to breathe, along with shortness of breath. In the afternoon, she was admitted to the infectious disease department of the Baoshan People's Hospital (a tertiary hospital near Longling County) for better treatment.

On January 29, the clinical laboratory examination showed that the white blood cell count was in normal range, but the neutrophil percentage was increased to 87.9%, along with the lymphocyte percentage decreased to 9.8%. According to the guideline for the diagnosis and treatment of 2019 novel coronavirus infected pneumonia (Trial 4th Edition), the patient was treated with antiviral therapy of lopinavir/ritonavir, IFN- α inhalation and oseltamivir (oseltamivir was withdrawn after once administration), and also intravenous injection of moxifloxacin, Xuebijing, methylprednisolone, and immunoglobulin. To reduce hypoxia and prevent respiratory muscle fatigue of the patient, the non-invasive mechanical ventilator was used under the advice and guidance of hospital specialist group.

On January 30, the patient could breathe easily under the ventilator, along with normal body temperature but paroxysmal cough. Considering that she got a severe diarrhea from January 30 night to January 31 morning, electrolyte replacement and rehydration were given for supportive treatment. In case of reducing the blood glucose level (postprandial glucose level around 9.6-14.6 mM), insulin was given intramuscularly. On January 31, the diarrhea symptom reduced significantly, but the patient showed severe electrolyte disturbance. The white blood cell count increased to $12.16 \times 10^9/L$, among which the neutrophil percentage increased to 92.4%. The C-reaction protein increased to 44.64mg/L, along with erythrocyte sedimentation rate increased to 88mm/h. Under the cooperation of multi-discipline team, the patient was diagnosed as critically ill type COVID-19 along with acute respiratory failure and acute diarrhea. Diabetes

and hypertension remained to be further determined.

On February 1, the patient showed no diarrhea and no shortness of breath when stay calmly, but with paroxysmal cough and small amount of white sputum. The white blood cell count continuously increased to $13.92 \times 10^9/L$, among which the neutrophil percentage increased to 95.1% and lymphocyte decreased to 2.9%. From February 1 evening to February 2 morning, the patient began to breathe fast with a respiratory rate of 35-44/min, which could not be improved by adjusting the parameter of the ventilator. The blood oxygen saturation was continuously lower than 86–90%. Under the guidance of the COVID-19 specialist team, the patient was urgently transferred to the ICU, and invasive tracheal cannula was performed to decrease the respiratory distress.

From February 2 to 4, the white blood cell count slightly decreased, among which the percentage of neutrophil increased to 82.2% and lymphocyte to 12.5% (both were still abnormal). In the early morning of February 4, the patient got a gastrorrhagia with a liquid amount around 230mL. Considering the low levels of red blood cell count and hemoglobin, anemia symptom was shown which might be caused by immune or inflammation related hemolysis. To modulate immune cell ratio, thymosin $\alpha 1$ was given from February 3. Although a blood transfusion was performed on February 4, the red blood cell count ($2.76 \times 10^{12}/L$) and hemoglobin concentration (92.00g/L) were still very low on February 5. On February 6, the serum bilirubin continuously increased, with the concentrations of DBil to $43.8 \mu M$ and I-Bil to $29.5 \mu M$, indicating liver injury possibility. The concentrations of CRP (82.69mg/L), PCT (0.102ng/mL), D-Dimer ($4.76 \mu g/mL$), and ProBNP (670.2pg/mL) were very high. Although the white cell count was in normal range ($8.38 \times 10^9/L$), but the neutrophil percentage began to increase again to a very high level (92.4%). All these results indicated that the anti-inflammatory effects of glucocorticoid, antiviral drugs and antibiotics might not work very well, and the gastrorrhagia was suspected to be caused by the side effects of glucocorticoid.

On February 7, considering the severe organ injury caused by inflammatory response and side effects, the glucocorticoid and antiviral therapy were withdrawn under the advice and guidance of the specialist group. The hUCMSCs adoptive transfer therapy was proposed. On February 8, the physical condition of the patient was re-evaluated. It was confirmed that she was critically ill type COVID-19, with severe pneumonia (mixed type), acute respiratory

distress, multi-organ injury (liver, respiratory system, and blood), moderate anemia, hypertension, type 2 diabetes, electrolyte disturbance, immunosuppression, acute gastrointestinal bleeding, and other symptoms. The family member and patient agreed to try hUCMSCs adoptive transfer therapy. The therapeutic scheme was then discussed and approved by the ethics committee of the hospital and consent forms were signed by the family member before the therapy.

Discussion

As shown in Figure 1, the allogenic hUCMSCs produced under GMP condition were administrated intravenously for three times (5×10^7 cells each time) on February 9, 12, and 15. During the therapy, antibiotics were given to prevent infection, and thymosin $\alpha 1$ was also given. After the first time adoptive transfer, no obvious side effects were observed, indicating it was well tolerated. As shown in Table 1, after the second administration, the serum bilirubin, CRP, and ALT/AST were gradually reduced, along with some other vital signs were also improved. The trachea cannula was also pulled off and the patient could ambulate on the ground from February 13 as well. As shown in Figure 2, after the second administration, the white blood cell count and neutrophil count decreased to the normal level, along with the lymphocyte count increased to normal level as well. More importantly, the counts of CD3⁺ T cell, CD4⁺ T cell, and CD8⁺ T cell were also remarkably increased to normal levels. It was also suggested that the immune modulating effects of thymosin $\alpha 1$ alone (From day 7 to day 12 in Figure 2) might be not very significant, indicating that hUCMSCs or combined with thymosin $\alpha 1$ could greatly reduce the inflammation response and help the recovery of antiviral immune cells and organs. Considering the characteristics of hUCMSCs, we speculated that they might homing to repair the injured tissues and neutralize the inflammatory cytokines (such as G-CSF and IL-6) by the expression of their receptors.

As shown in Figure 3, by comparing the chest CT images taken on January 29 to February 16 and February 21, it can be seen that the pneumonia was greatly relieved. On February 17, the patient was transferred out of ICU, and most of the vital signs and clinical laboratory indexes recovered to normal level. The throat swabs tests reported negative on both February 17 and February 19.

Conclusions

As a conclusion, we proposed that the adoptive transfer therapy of hUCMSCs might be an ideal choice to be used or combined with other immune modulating agents. Although only one case was shown here, it would also be very important to inspire more similar clinical practice to treat such critically ill COVID-19 patients.

Ethical Approval and Consent to participate

The study was approved by the Ethics Committee of the Baoshan People's Hospital and informed consent was confirmed by the participants.

Consent for publication

Informed consent for publication was obtained from all authors and participants.

Availability of supporting data

The data supporting the results were included within the article.

Competing interests

All authors declare no competing interests.

Funding

This study was supported by the grants from Shenzhen Municipal Health Commission (SZSM201612071), the Ministry of Science and Technology of China (YCZYPT[2018] 03-1), and the Yunnan Science & Technology (2016RA093, 2018ZF007-03, 2019ZF002).

Authors' contributions

Liang B., Li T., and Hu M. had full access to all of the data in the study and take responsibility for the accuracy of the data. Chen J. Wu H. and Qian C. analyzed the data. Gao Y. wrote the manuscript. Yang W., Li Y., Li J., Nie F., Ma Z., Yang M., and Nie P. participated the study and help to collect the data.

Acknowledgements

We thank the grants supported by the Shenzhen Municipal Health Commission (SZSM201612071), the Ministry of Science and Technology of China (YCZYPT[2018] 03-1), and the Yunnan Science & Technology (2016RA093, 2018ZF007-03, 2019ZF002).

Authors' information

Bing Liang[#], Wenjie Yang[#], Jianchun Li, Fangang Nie, Mingxi Yang

Department of Critical Care Medicine, Baoshan People's Hospital, Baoshan 678000, China

Junhui Chen[#], Congtao Yu

Intervention and Cell Therapy Center, Peking University Shenzhen Hospital, Shenzhen 518035, China

Tao Li[#]

Yunnan Yasheng Medical Technology Co., Ltd., Kunming 650021, China

Haiying Wu[#], Chuanyun Qian^{*}

Emergency Department of the First Affiliated Hospital of Kunming Medical University, EICU/MICU, Kunming 650032, China

Yanjiao Li, Zhaoxia Ma

Yunnan Key Laboratory for Basic Research on Bone and Joint Diseases & Yunnan Stem Cell Translational Research Center, Kunming University, Kunming 650214, China

Panrong Nie

Department of Neonatology, Baoshan People's Hospital, Baoshan, 678000, China

Yanfeng Gao^{*}

School of Pharmaceutical Sciences (Shenzhen), Sun Yat-sen University, Shenzhen 517108, China; Intervention and Cell Therapy Center, Peking University Shenzhen Hospital, Shenzhen 518035, China

Min Hu^{*}

Yunnan Key Laboratory for Basic Research on Bone and Joint Diseases & Yunnan Stem Cell Translational Research Center, Kunming University, Kunming 650214, China; Intervention and Cell Therapy Center, Peking University Shenzhen Hospital, Shenzhen 518035, China; Yunnan

Jici Institute for Regenerative Medicine co., Ltd., Kunming 650106, China

These authors contribute equally.

* Correspondence to: E-mail: huminyнкm@163.com (Hu M.); qianchuanyun@126.com (Qian C.); yfgao@hotmail.com (Gao Y.)

References

1. Data were cited from <https://news.qq.com/zt2020/page/feiyan.htm>.
2. Huang C, Wang Y, Li X, Ren L, Zhao J, Hu Y, Zhang L, Fan G, Xu J, Gu X, Cheng Z, Yu T, Xia J, Wei Y, Wu W, Xie X, Yin W, Li H, Liu M, Xiao Y, Gao H, Guo L, Xie J, Wang G, Jiang R, Gao Z, Jin Q, Wang J, Cao B. Clinical features of patients infected with 2019 novel coronavirus in Wuhan, China. *Lancet*. 2020; doi: 10.1016/S0140-6736(20)30183-5.
3. Wang D, Hu B, Hu C, Zhu F, Liu X, Zhang J, Wang B, Xiang H, Cheng Z, Xiong Y, Zhao Y, Li Y, Wang X, Peng Z. Clinical Characteristics of 138 Hospitalized Patients With 2019 Novel Coronavirus-Infected Pneumonia in Wuhan, China. *JAMA*. 2020; doi: 10.1001/jama.2020.1585.
4. Xu Z, Shi L, Wang Y, Zhang J, Huang L, Zhang C, Liu S, Zhao P, Liu H, Zhu L, Tai Y, Bai C, Gao T, Song J, Xia P, Dong J, Zhao J, Wang F. Pathological findings of COVID-19 associated with acute respiratory distress syndrome. *Lancet Respir Med*. 2020; pii: S2213-2600(20)30076-X.
5. Shang L, Zhao J, Hu Y, Du R, Cao B. On the use of corticosteroids for 2019-nCoV pneumonia. *Lancet*. 2020; pii: S0140-6736(20)30361-5.
6. Zumla A, Hui DS, Azhar EI, Memish ZA, Maeurer M. Reducing mortality from 2019-nCoV: host-directed therapies should be an option. *Lancet*. 2020; doi: 10.1016/S0140-6736(20)30305-6.
7. Le Blanc K, Rasmusson I, Sundberg B, Götherström C, Hassan M, Uzunel M, Ringdén O. Treatment of severe acute graft-versus-host disease with third party haploidentical mesenchymal stem cells. *Lancet*. 2004; 363(9419):1439-41.
8. Fan XL, Zhang Y, Li X, Fu QL. Mechanisms underlying the protective effects of mesenchymal stem cell-based therapy. *Cell Mol Life Sci*. 2020; doi:10.1007/s00018-020-03454-6.
9. Darwish I, Mubareka S, Liles WC. Immunomodulatory therapy for severe influenza. *Expert Rev Anti Infect Ther*. 2011; 9(7):807-22.

Hospital	0	1	2	3	4	5	6	7	8	9	10	11	12	13	14	15	16	17	18	19	20	21	
Fever																							
Diarrhea																							
ARDS																							
ICU																							
Non-invasive																							
Invasive ventilator																							
GI bleeding																							
Treatment																							
Antibiotics																							
Antiviral																							
Corticosteroid																							
Thymosin α 1																							
Immunoglobulin																							
hUCMSC																							
Date (*diagnosed)	Jan 27	Jan 28*	Jan 29	Jan 30	Jan 31	Feb 1	Feb 2	Feb 3	Feb 4	Feb 5	Feb 6	Feb 7	Feb 8	Feb 9	Feb 10	Feb 11	Feb 12	Feb 13	Feb 14	Feb 15	Feb 16	Feb 17	

Figure 1. The major symptoms and treatment of the critically ill COVID-19 patient

Table 1. The major clinical laboratory characteristics of the patient

	Normal range	Days after disease onset										
		3	6	8	10	12	13*	14	16*	17	19*	21
Creatinine (μM)	41-81	48	52.8	39.1	40.7		33.6	41.5	41.1	40.8	49.1	
Dbil (μM)	0-8	2.8	12.6	6.8	43.8	14.5	11	9.9	6.6	6.6	5.9	
Ibil (μM)	1.7-21	4.41	10.93	11.8	29.5	14.1	12.5	13.2	8.4	9.8	11.90	
Tbil (μM)	≤21	7.22	23.53	18.6	73.3	28.6	23.5	23.1	15	16.4	17.8	
Albumin (g/L)	40-55	34	30.7	45.7	39.2	38.4	38.8	41.5	41.6	43.3	42.4	
ALT (U/L)	7-40	25.3	21.1	18.2	22.7	25.3	37.1	53.5	45.4	37	25.7	
AST (U/L)	13-35	30.3	21.9	19.4	20.6	23.8	38.3	45.8	31.7	26.1	19.9	
CRP (mg/L)	0-3	69.68		34.61	82.69	22.63	33.2	35.58	27.9	11.93		
PCT (ng/mL)	0-0.05	0.01	0.01	0.049	0.102		0.07	0.161	0.153	0.047		
D-dimer (μg/mL)	0-0.5		2.63	2.28	4.76		2.23	2.08	2.56	2.01	2.16	1.34
proBNP (pg/mL)	0-325	4.012	151.7	629.9	670.2	373			153.1			

* Indicates the day of hUCMSCs therapy

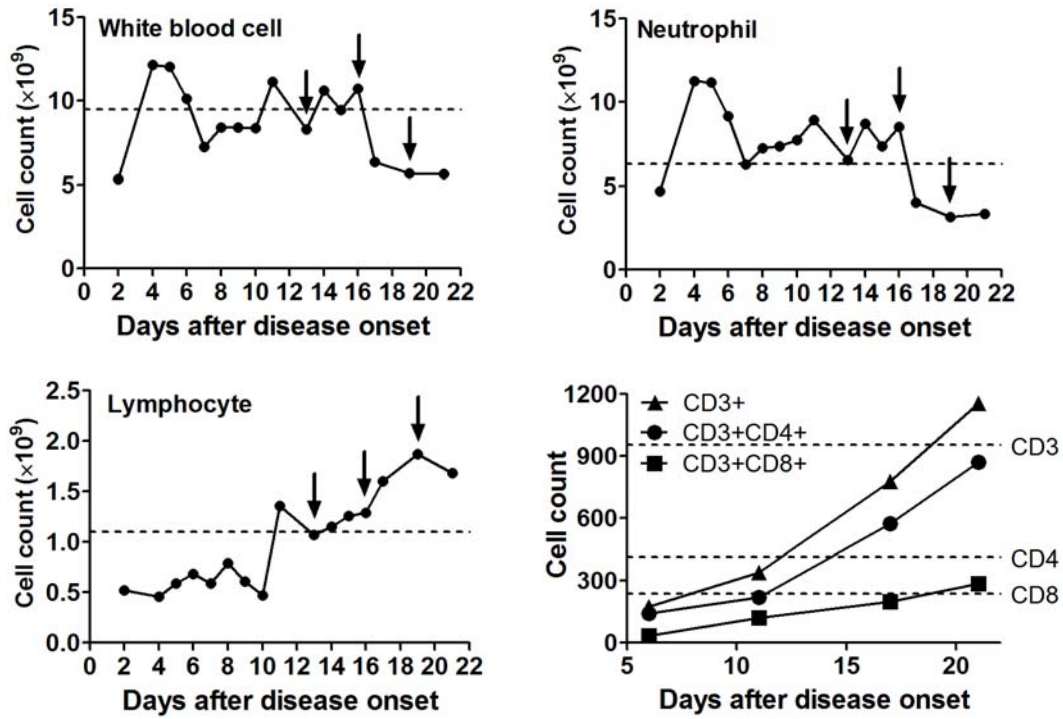


Figure 2. The dynamic changes of the immune cell counts of the patient. The arrows indicate the day of hUCMSCs therapy. To the white blood cell (normal range $3.5\text{--}9.5\times 10^9/\text{L}$) and neutrophil (normal range $1.8\text{--}6.3\times 10^9/\text{L}$), the dash line indicates upper threshold. While to the lymphocyte (normal range $1.1\text{--}3.2\times 10^9/\text{L}$) and T cell subsets, the dash line indicates lower threshold.

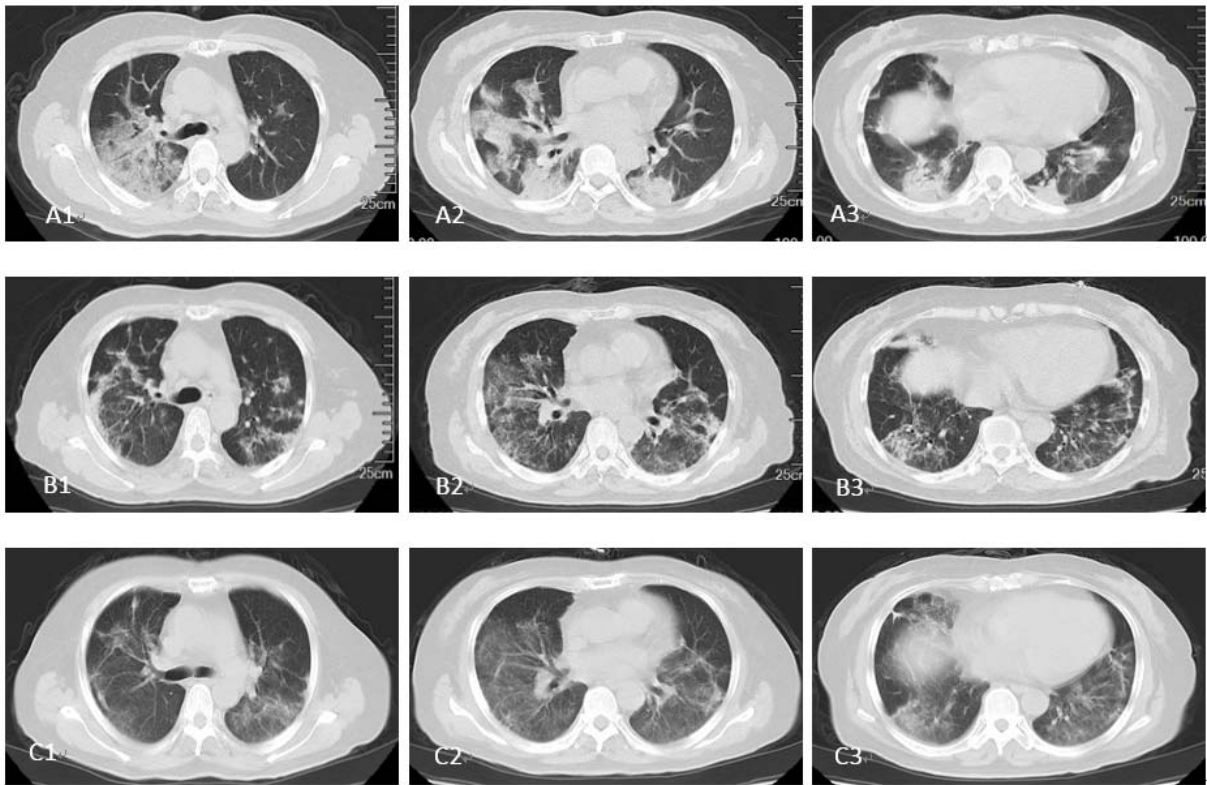


Figure 3. The typical CT images of the lung. A1-A3) CT images on January 29 indicate that there are lesions and mass density increasing shadow in both left and right lung. The ground-glass opacity, nonhomogeneous density, and air bronchus can be seen in the right lung. B1-B3) CT images on February 16 indicate the significant relief in both left and right lung. Only some Stripe shadow and small pieces of ground-glass opacity can be seen. C1-C3) CT images on February 21 indicate the further relief in both left and right lung. Most of the ground-glass opacity lightened, or even disappeared.