

# Type I Hypersensitivity in Ferrets Following Exposure to SARS-CoV-2 Inoculum: Lessons Learned

Daniel Layton<sup>1</sup>, Kathie Burkett<sup>1</sup>, Glenn A. Marsh<sup>1</sup>, Nagendrakumar B. Singanallur<sup>1</sup>, Jennifer Barr<sup>1</sup>, Rachel Layton<sup>1</sup>, Sarah-Jane Riddell<sup>1</sup>, Sheree Brown<sup>1</sup>, Lee Trinidad<sup>1</sup>, Gough G. Au<sup>1</sup>, Alexander J. McAuley<sup>1</sup>, Suzanne Lowther<sup>1</sup>, James Watson<sup>1</sup> and Seshadri S. Vasani<sup>1,2,\*</sup>

<sup>1</sup>Commonwealth Scientific and Industrial Research Organisation, Australian Centre for Disease Preparedness, Geelong, Victoria, Australia and <sup>2</sup>University of York, Department of Health Sciences, York, England, UK

\*Corresponding Author: Prof Seshadri S Vasani, Health and Biosecurity, CSIRO Australian Centre for Disease Preparedness, 5 Portarlington Road, Geelong, Victoria 3220, Australia. Email [vasan.vasani@csiro.au](mailto:vasan.vasani@csiro.au). ORCID 0000-0002-7326-3210.

## Abstract

This case report discusses Type I hypersensitivity in ferrets following exposure to severe acute respiratory syndrome coronavirus 2 (SARS-CoV-2) inoculum, observed during a study investigating the efficacy of candidate COVID-19 vaccines. Following a comprehensive internal root-cause investigation, it was hypothesized that prior prime-boost immunization of ferrets with a commercial canine C3 vaccine to protect against the canine distemper virus had resulted in primary immune response to fetal bovine serum (FBS) in the C3 preparation. Upon intranasal exposure to SARS-CoV-2 virus cultured in medium containing FBS, an allergic airway response occurred in 6 out of 56 of the ferrets. The 6 impacted ferrets were randomly dispersed across study groups, including different COVID-19 vaccine candidates, routes of vaccine candidate administration, and controls (placebo). The root-cause investigation and subsequent analysis determined that the allergic reaction was unrelated to the COVID-19 vaccine candidates under evaluation. Histological assessment suggested that the allergic response was characterized by eosinophilic airway disease; increased serum immunoglobulin levels reactive to FBS further suggested this response was caused by immune priming to FBS present in the C3 vaccine. This was further supported by *in vivo* studies demonstrating ferrets administered diluted FBS also presented clinical signs consistent with a hyperallergic response, while clinical signs were absent in ferrets that received a serum-free SARS-CoV-2 inoculum. It is therefore recommended that vaccine studies in higher order animals should consider the impact of welfare vaccination and use serum-free inoculum whenever possible.

**Key words:** allergy; COVID-19; ferrets; fetal bovine serum; hypersensitivity; vaccines.

## INTRODUCTION

The severe acute respiratory syndrome coronavirus 2 (SARS-CoV-2) pandemic, to date, has caused circa 166 million

infections world-wide and over 3.5 million deaths,<sup>1</sup> which has led to the development of vaccines and therapeutics at an unprecedented rate. A key to this rapid development is the ability to evaluate candidates in preclinical animal models. Typically,

Received: February 3, 2021. Accepted: April 16, 2021

© The Author(s) 2021. Published by Oxford University Press on behalf of the National Academies of Sciences, Engineering, and Medicine. This is an Open Access article distributed under the terms of the Creative Commons Attribution Non-Commercial License (<http://creativecommons.org/licenses/by-nc/4.0/>), which permits non-commercial re-use, distribution, and reproduction in any medium, provided the original work is properly cited. For commercial re-use, please contact [journals.permissions@oup.com](mailto:journals.permissions@oup.com)

outbred, high-order mammals with respiratory similarities to humans, including suitable homology to the angiotensin-converting enzyme 2 (ACE2) receptor, are of higher value in these studies.<sup>2</sup> These include ferrets,<sup>3,4</sup> hamsters,<sup>5</sup> and Rhesus macaques.<sup>6</sup> It is of critical importance to know the limitations of each model when designing and carrying out preclinical vaccine evaluation. Immediate Type I hypersensitivity reaction or anaphylaxis following immunization with vaccines have been reported in both humans and animals. Such reactions have been attributed to an IgE-mediated reaction to proteins of either bovine or porcine origin used in either vaccine production or as a stabilizer in vaccine formulations.<sup>7</sup> An apparent hypersensitivity reaction occurred in ferrets following intranasal challenge with an inoculum containing SARS-CoV-2 virus during a vaccine trial involving candidate COVID-19 vaccines. In this case report, we present the outcomes of an internal root cause investigation that was undertaken using the Ishikawa (fishbone) technique to determine the potential causes that led to these events to ensure the lessons learned can be shared.

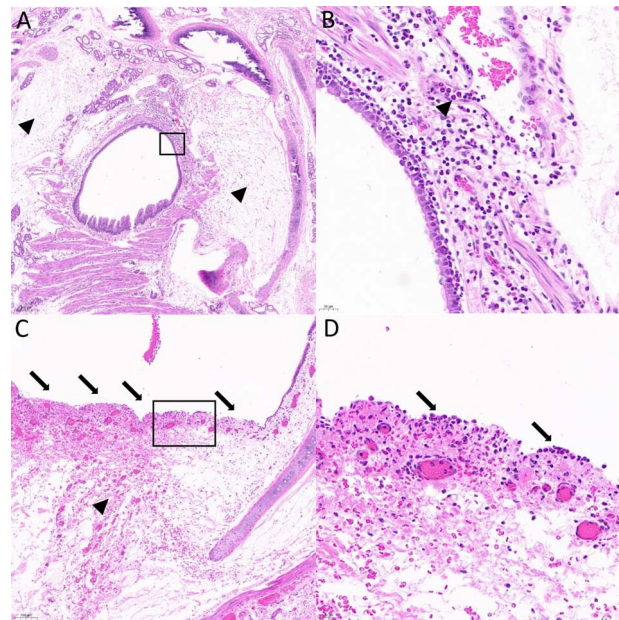
## RESULTS

### Case Presentation

The first incident occurred after intranasal virus challenge. In an initial cohort of 28 ferrets, 2 ferrets presented with respiratory distress, epistaxis, and hemoptysis within 1 hour of viral challenge with an inoculum comprising SARS-CoV-2 virus in culture Dulbecco's Modified Eagle Medium with 2% Fetal Bovine Serum (DMEM + 2% FBS). Both animals were euthanized in accordance with ethical practice and a "5 Why" investigation initiated. Several hypotheses to explain the incident were considered, including potential sources of contamination (chemical and microbiological) and respiratory hypersensitivity. An additional incident occurred in a subsequent cohort of 28 ferrets (prior to completion of the initial investigation) with a further 4 showing respiratory distress within 1 hour of challenge. Three of these ferrets recovered; however, 1 displayed prolonged clinical signs and required euthanasia. Affected ferrets showed varying degrees of respiratory distress, primarily on expiration, with forced to paroxysmal exhalation, suggestive of functional lower airway obstruction. Some sneezing was also evident and appeared to be due to retrograde passage of mucus into the internal nares.

### Necropsy Findings and Histopathological Investigations Suggested Eosinophilic Infiltrate as a Contributing Factor

Necropsies were performed on the 3 euthanized ferrets. Histopathological findings included moderate to severe multifocal to coalescing ulcerative eosinophilic laryngotracheitis, bronchitis, and bronchiolitis with moderate to severe edema and/or hemorrhage, consistent with a peracute to acute hypersensitivity reaction; also described as anaphylaxis (Figure 1). Additional findings included severe edema in bronchial submucosa, moderate infiltrate of eosinophils and mononuclear cells in the bronchial mucosa, with eosinophilic migration present in adjacent blood vessels. Additionally, regionally extensive areas of epithelial ulceration, submucosal edema, and hemorrhage in the trachea were observed. Ulcerated regions showed a light infiltration of eosinophils in superficial lamina propria with some lining the denuded basement membrane of the tracheal mucosa. Numerous extravasated

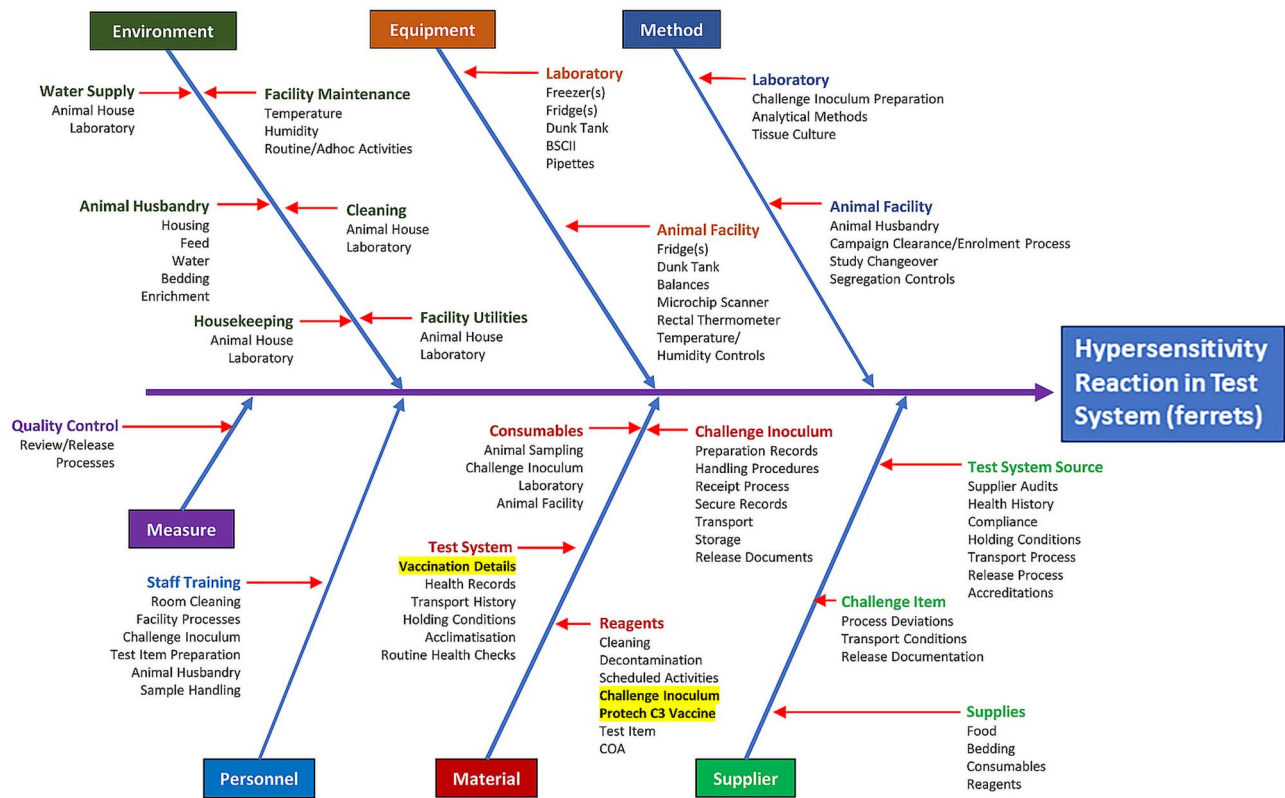


**Figure 1:** Histopathology in 1 of the ferrets that developed peracute respiratory distress after receiving the SARS-CoV-2 inoculum intranasally. (A) Severe edema in bronchial submucosa (arrowheads). Black rectangular box indicates the region shown in panel B. (B) Moderate infiltrate of eosinophils and mononuclear cells in the bronchial mucosa. There are also eosinophils marginating in adjacent blood vessels (arrowhead). (C) Regionally extensive area of epithelial ulceration (arrows), submucosal edema, and hemorrhage (arrowhead) in the trachea. Black rectangular box indicates the region shown in panel D. (D) In the ulcerated region, there is a light infiltrate of eosinophils in superficial lamina propria and some lining the denuded basement membrane of the tracheal mucosa (arrows). There are also numerous extravasated erythrocytes (hemorrhage) and a moderate amount of fibrin admixed with edema in the lamina propria. All slides are stained with H&E stain. Magnification: (A) at 5x; (B) at 40x; (C) at 10x; and (D) at 40x.

erythrocytes (hemorrhage) and moderate amounts of fibrin admixed with edema in the lamina propria were also observed. These findings suggested the presence of eosinophilic airway disease. Similar histopathological changes were observed in the ferrets that were euthanized as well as those that recovered from the severe anaphylaxis reaction. Furthermore, at the conclusion of the study, histopathological analysis revealed similar infiltrate of eosinophils in respiratory tissues in multiple ferrets, including those that displayed clinical signs immediately after challenge as well as those that did not. Significantly, this histopathological assessment indicated an underlying allergic process suggesting sensitization of this cohort of ferrets to an undefined antigen.

### Root Cause Investigation

**Indication of Type I Hypersensitivity Reaction and Potential C3 Vaccine Involvement.** An internal root-cause investigation was undertaken using the Ishikawa technique to systematically categorize and analyze a cross-section of processes and influences that may have contributed to the hypersensitivity reaction (Figure 2).<sup>8,9</sup> The Ishikawa technique can be employed for cause and effect analysis and is commonly used in quality management to help identify all potential causes of an issue. Processes audited included (not limited to) animal source; transport and husbandry; animal interventions/treatments such as protective vaccination against canine distemper (C3); preparation, handling, and storage of virus inoculum and test

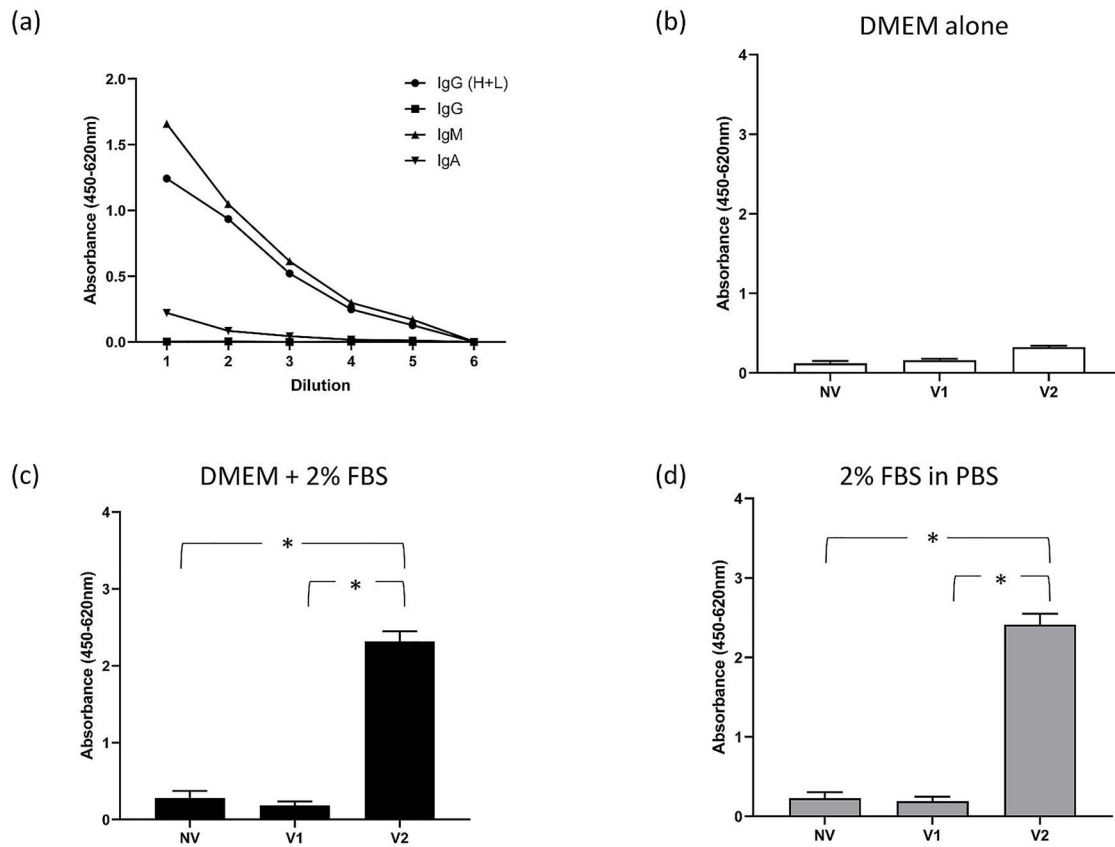


**Figure 2:** Ishikawa (fishbone) diagram for root cause analysis of hypersensitivity reaction in ferrets. A comprehensive review of all possible causal factors contributing to the observed clinical signs was visualized in an Ishikawa (fishbone) diagram. The diagram lists potential causal factors in useful categories to aid a comprehensive investigation. All factors were reviewed, and those highlighted were further examined after a systematic process of elimination.

items; and environmental conditions as well as adherence to internal policies and procedures. The investigation outcomes, in conjunction with observed clinical signs and histopathological findings, indicated an immediate Type I hypersensitivity reaction as characterized by anaphylaxis in affected ferrets. Post-mortem histopathological examination of ferret tissues showed consistent evidence of eosinophil infiltration in ferrets across all study groups. Although the pathophysiology of acute anaphylaxis in ferrets is not well described, it is reasonable to generalize from related species. Two critical factors considered in this type of response are the proximate trigger and the prior sensitization that primes the immune system. The timing of both observed incidents, occurring a short period after viral challenge, strongly indicated the challenge inoculum as the triggering agent, with a commercial canine C3 vaccine that included a canine distemper virus component and media constituents acting as the priming agent. This was further reinforced by the investigation whereby it was noted that all clinically affected ferrets received 2 doses of the C3 vaccine (prime and boost), whereas no such observations were made with ferrets receiving a single dose of the C3 vaccine due to being incorporated into initial characterization of the SARS-CoV-2 infection prior to their second C3 vaccination. Interestingly, similar histopathological changes have been observed in the tissues of “non-impacted” ferrets from previous studies that had received a single dose of the C3 vaccine (prime only). It should be noted that the allergic reaction in ferrets was not a reflection on the safety or efficacy of the C3 vaccine itself because (1) the vaccine is commercially licensed for dogs only and was therefore used “off label” in ferrets as a welfare vaccination in accordance

with the Australian Veterinary Association recommendations for ferret vaccinations, and (2) it is not typical that ferrets (or dogs) are intranasally exposed to viral culture fluid components outside of laboratory conditions.

**High Levels of Serum Immunoglobulin to FBS.** Due to the absence of pre-exposure to the SARS-CoV-2 virus, it was hypothesized that components of the tissue culture media used for viral propagation contributed to the allergic response. Ferrets received 2 doses of the C3 vaccine containing live attenuated canine distemper virus, live attenuated canine adenovirus type 2 (infectious hepatitis), and live attenuated canine parvovirus. As with many veterinary vaccines, the C3 vaccine contained fetal bovine serum (FBS) inherent with vaccine manufacture, which could potentially induce a strong immune response. Empirical data from mouse studies investigating albumin-induced asthma give further credence to this hypothesis.<sup>10</sup> Therefore, the presence of anti-FBS antibodies in sera of these ferrets could possibly correlate with the exhibition of hypersensitivity reactions. A ferret anti-FBS serum Enzyme-Linked Immuno-Sorbent Assay (ELISA) was developed in-house to determine if a possible serological response had occurred. A goat anti-ferret (H + L) antibody conjugated with horse radish peroxidase (Abcam, Australia) was used as a secondary antibody, and the optimal concentration was established by titration with normal ferret serum coated as ELISA plate coating at 1:25 dilution in carbonate-bicarbonate buffer (pH 9.6). The working dilution of the secondary antibody conjugate in a 3,3',5,5'-tetramethylbenzidine (Thermo Fisher Scientific, Australia) system measured at 450 nm was determined to be 1:4000 (Figure 3a). To identify if the ferret sera had antibodies



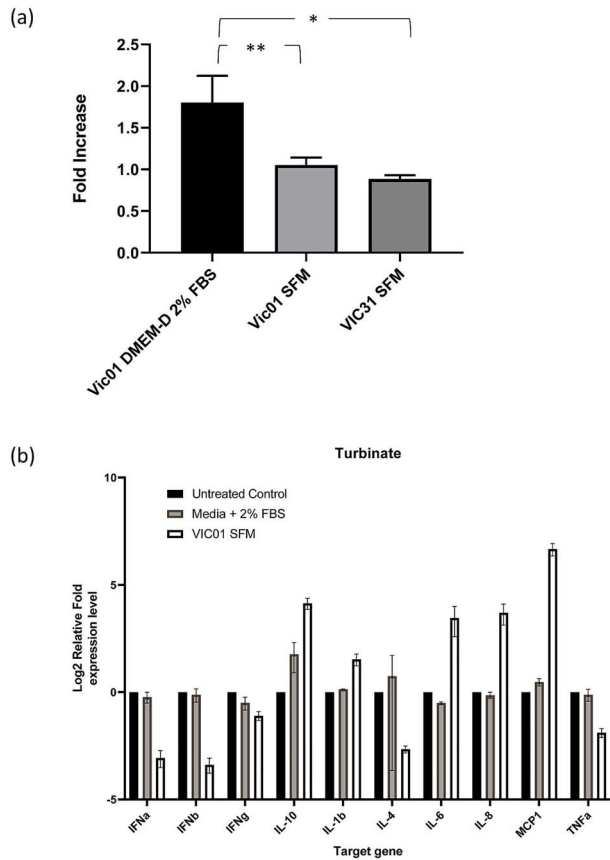
**Figure 3:** Ferret sera is reactive with FBS but not DMEM. (a) Titration of goat-anti-ferret antibodies to obtain optimal working dilution for the assay. The ferrets had received either no C3 vaccination (NV), 1 C3 vaccination (V1), or 2 C3 vaccinations (V2). The absorbance values (450–620 nm) at 1 in 16 serum dilution is shown with error bars representing the standard error of the mean value (b–d). The mean values between responses in different groups was significantly different ( $P < .05$ ).

to components of FBS (Thermo Fisher Scientific, Australia), 96-well ELISA plates (Nunc, Australia) were coated with 200  $\mu$ L of either DMEM (Thermo Fisher Scientific, Australia), DMEM containing FBS (2%), or 2% FBS in Phosphate-Buffered Saline (PBS) alone. Sera were tested for reactivity to FBS comparing between ferrets that had not received C3 vaccine ( $n=8$ ), ferrets that had received a single dose of C3 vaccine ( $n=26$ ), and ferrets that had been administered 2 doses of C3 vaccine ( $n=53$ ). We used a Kruskal Wallis with Dunns multiple comparison test to determine statistical significance between groups. While the sera collected from ferrets that had not received C3 vaccine and ferrets that had received a single dose of C3 vaccine did not show high levels of reactivity to DMEM, DMEM + FBS (2%), or FBS (2%) alone (Figure 3b–d; Supplementary Table 1), those collected from the ferrets that had been administered 2 doses of C3 vaccine showed significantly higher reactivity to DMEM, DMEM + FBS (2%), and FBS (2%) (Figure 3b–d; Supplementary Table 1), suggestive of an active immune response to a component(s) of FBS.

**In Vivo Testing of FBS Reactivity.** To further confirm the ability of FBS to generate a hypersensitivity reaction, we developed stocks of SARS-CoV-2 without FBS. Vero E6 cells were adapted to Virus Production Serum-Free Medium (VP-SFM; Thermo Fisher Scientific, Australia) by serial passage. The adapted cells were inoculated with the Australian SARS-CoV-2 isolates hCoV-19/Australia/VIC01/2020 (VIC01) or hCoV-19/Australia/VIC31/2020 at a multiplicity of infection of 0.0025.

Harvest of the supernatant at 36 hours post-infection resulted in a virus stock with a median titer close to  $1 \times 10^6$  TCID<sub>50</sub>/mL, suggesting that virus growth was not impacted by the use of VP-SFM. An ELISA assay using ferret serum with irradiated serum-free virus stocks or 2% FBS as the coating material demonstrated significantly ( $P < .05$ ) lower reactivity to VP-SFM VIC01 or an alternative strain VP-SFM hCoV-19/Australia/VIC31/2020 compared with 2% FBS, further supporting the hypothesis that FBS in the original virus stock was serving as an allergen (Figure 4a). We then performed a small-scale *in vivo* study using animals challenged with either the VP-SFM VIC01 virus stocks ( $n=4$ ) or 2% FBS as the inoculum ( $n=2$ ). The results were compared with a single control ferret. In this study, we observed clinical presentation of hyperallergic response (characterized by acute respiratory distress) in 1 of the 2 ferrets receiving the 2% FBS inoculum. These clinical signs were consistent with those previously observed. Furthermore, no clinical signs were observed in ferrets receiving the VP-SFM VIC01 providing further evidence that the ferrets had developed a Type I hypersensitivity to FBS. We further investigated the immune response in these ferrets by performing quantitative PCR for a range of ferret cytokines from nasal turbinates between 3 and 4 hours post inoculation from ferrets receiving either FBS, VP-SFM VIC01, or no inoculum (Figure 4b). Although this study was observational only and we were unable to perform statistical analysis, we observed higher levels of interleukin (IL), especially IL-4 transcript in the ferret showing reactivity to FBS (compared with those not displaying clinical signs) which has previously





**Figure 4:** ELISA and RT-qPCR of ferret samples. (a) ELISA of ferret sera showed that 2% FBS reacts significantly higher than VP-SFM VIC01 and VP-SFM VIC31 virus stocks. (b) RT-qPCR of nasal turbinates from inoculated vs control ferrets show the differences in the expression of cytokines. The mean values and standard error of the mean were presented and responses between different groups were significantly different ( $P < .05$ ).

been shown to be strongly associated with an allergic reaction.<sup>11</sup> In ferrets receiving the VP-SFM VIC01, we observed high levels of IL-6, IL-8, and monocyte chemoattractant protein-1 (MCP1), which have all been associated with infection with SARS-CoV-2.<sup>12,13</sup> Furthermore, we observed low levels of IL-4, suggesting no allergic reaction was occurring. Interestingly, we observed a low level of 2 key antiviral cytokines (IFN $\alpha$  and IFN $\beta$ ) in ferrets receiving VP-SFM VIC01. These cytokines are Type 1 interferons that are commonly responsible for limiting viral spread early in the course of infection. As it has been demonstrated that coronaviruses may have a delayed and weak induction of key interferons (IFNs), it may be worthwhile to investigate these findings further.<sup>12</sup>

## DISCUSSION

Preclinical evaluation of potential vaccines and therapeutics in higher order animals is complex and requires a significant amount of regulation, resources, and cost. In response to the current SARS-CoV-2 pandemic, it was critical that these preclinical models were developed and deployed in an expedient manner. This case report describes an unexpected event in ferrets following intranasal challenge with a tissue culture–derived SARS-CoV-2 virus, and it is concluded that the pre-exposure to FBS proteins through routine husbandry vaccination can result in an

immune priming followed by an anaphylaxis-type response to intranasal administration of FBS containing inoculum.

It has been previously demonstrated that components of FBS, especially albumin, are a potential cause of allergic reaction to human therapeutics.<sup>14</sup> Prior exposure to highly immunogenic antigens such as ovalbumin followed by intratracheal administration have been used extensively to induce acute asthma in rodents.<sup>15</sup> Additionally, ovalbumin has been shown to induce anaphylaxis in mice when 2 intraperitoneal doses were administered followed by intratracheal exposure.<sup>16</sup> In this study, severity of the allergic reaction also correlated with observed IgE and IgG levels. Furthermore, studies by Ohmori et al<sup>17</sup> have demonstrated that the development of immediate-type allergic reactions following vaccination in dogs was IgE-mediated Type I hypersensitivity as indicated by high levels of IgE directed toward FBS proteins. Further work by this group has demonstrated by immunoblot analysis that a number of FBS proteins reacted with IgE from allergic dogs, with the majority speculated to correspond to albumin.<sup>18</sup> Additionally, it is well established that eosinophilic infiltrate is strongly correlated to allergic immune response.<sup>19</sup> Eosinophilic infiltration was evident through histopathological analysis of ferret tissues from animals that had received either 1 or 2 doses of the C3 vaccine. Important to these findings is the timing of histopathological analysis. Most tissues were analyzed between 3 and 14 days post viral challenge with SARS-CoV-2, allowing for significant further development of eosinophilic infiltration and tissue damage following intranasal challenge. This study demonstrates a strong serological response to FBS proteins following canine C3 vaccination in ferrets. Interestingly, retrospective analysis of ferret sera showed that ferrets that had received only a single dose of the C3 vaccine did not generate a detectable serological response above background compared with unvaccinated ferrets, suggesting that, at least from a serological perspective, detection of systemic antibodies required a prime and boost. This finding gives further evidence to the hypothesis that the serological immune response was likely induced through routine husbandry vaccination with C3 vaccine. This was further supported with the generation of serum-free virus stocks using virus production serum-free medium (VP-SFM; Thermo Fisher Scientific, Australia) to which ferret sera appeared to have reduced reactivity. Additionally, we empirically demonstrated the ability of FBS alone to induce the observed hypersensitivity reaction in 1 of 2 ferrets tested, and this reaction correlated with an increase in IL-4 production. Furthermore, we demonstrated that in 4 ferrets receiving VP-SFM VIC01, we were unable to detect a hypersensitivity reaction either clinically or by cytokine measurement. It is noteworthy that other published ferret models have not reported the use of C3 vaccination or any hypersensitivity reaction.<sup>2</sup>

## CONCLUSION

A thorough assessment must be undertaken when selecting animal models for vaccine efficacy studies. In mammals where preventive vaccinations are mandated for welfare reasons, care should be taken in reviewing all previous interventions relating to the test subjects. In our experience, it is therefore critical that a serum-free inoculum be prepared and tested before any such major studies are carried out.

## Acknowledgments

We acknowledge the 2 “test item” providers for the ferret studies. We are grateful for support from our colleagues at the Australian

Centre for Disease Preparedness (<https://www.grid.ac/institute/s/grid.413322.5>) (especially pathologists John Bingham, William Suen, and Hannah Bender) and the Victorian Infectious Diseases Reference Laboratory (especially Mike Catton and Julian Druce for providing the VIC01 isolate of SARS-CoV-2). We sincerely thank the following experts in chemistry and toxicology for their advice: Jayanta Halder (Associate Professor, JNCASR, Bengaluru, India), Anupama Kumar (Team Leader, Environmental Toxicology and Chemistry, CSIRO), Brian Priestly (Toorak Gardens, South Australia), and Jenny Stauber (Chief Research Scientist, Land and Water, CSIRO). We also thank our CSIRO Manufacturing colleagues (Carl Braybrook, Pam Hoobin, Marc McEwan, Roger Mulder, and Tom Nebl) for analytical support. Ferret serum samples were obtained from various studies conducted in ferrets following review and approval by the Animal Ethics Committee of the Australian Centre for Disease Preparedness.

**Additional information.** The commercial canine C3 vaccine is licensed for use only in dogs. Since no other vaccine for canine distemper is registered in Australia, the Australian Veterinary Association recommends off-label use of this vaccine in ferrets for the sole purpose to prevent infections with canine distemper virus. We do not in any way question the safety and efficacy of this vaccine for use in dogs. Our intention is to alert other researchers to unexpected reactions that may occur during studies with higher order mammals under certain circumstances and to the advantages of serum-free inoculum for challenge in vaccine efficacy studies.

**Financial support.** This work was conducted with funding to the CSIRO from the Coalition for Epidemic Preparedness Innovations (CEPI). SSV is also grateful to CSIRO Future Science Platforms, Department of Finance, and National Health and Medical Research Council of Australia for funding.

**Potential conflicts of interest.** All authors: No reported conflicts.

## References

- Dong E, Du H, Gardner L. An interactive web-based dashboard to track COVID-19 in real time. *Lancet Infect Dis* 2020; 20(5):533–534.
- Muñoz-Fontela C, Dowling WE, Funnell SGP et al. Animal models for COVID-19. *Nature* 2020; 586(7830):509–515.
- van den Brand JM, Haagmans BL, Leijten L et al. Pathology of experimental SARS coronavirus infection in cats and ferrets. *Vet Pathol* 2008; 45(4):551–562.
- Stittelaar KJ, de Waal L, van Amerongen G et al. Ferrets as a novel animal model for studying human respiratory syncytial virus infections in immunocompetent and immunocompromised hosts. *Viruses* 2016; 8(6):168.
- Deming D, Sheahan T, Heise M et al. Vaccine efficacy in senescent mice challenged with recombinant SARS-CoV bearing epidemic and zoonotic spike variants. *PLoS Med* 2006; 3(12):e525.
- Miller LA, Royer CM, Pinkerton KE et al. Nonhuman primate models of respiratory disease: past, present, and future. *ILAR J* 2017; 58(2):269–280.
- McNeil MM, DeStefano F. Vaccine-associated hypersensitivity. *J Allergy Clin Immunol*. 2018; 141(2):463–472.
- Gittleston PL. Standards of good practice for the conduct of regulated nonclinical safety studies. *Comprehensive Toxicology* 2010; 3:87–96.
- Becker RA. Standards of good practice for the conduct of safety (nonclinical toxicity) studies for regulatory use. *Comprehensive Toxicology* 2018; 9:64–74.
- Nials AT, Uddin S. Mouse models of allergic asthma: acute and chronic allergen challenge. *Dis Model Mech* 2008; 1(4–5):213–220.
- Gour N, Wills-Karp M. IL-4 and IL-13 signaling in allergic airway disease. *Cytokine* 2015; 75(1):68–78.
- Sa Ribero M, Jouvenet N, Dreux M et al. Interplay between SARS-CoV-2 and the type I interferon response. *PLoS Pathog* 2020; 16(7):e1008737.
- Leisman DE, Ronner L, Pinotti R et al. Cytokine elevation in severe and critical COVID-19: a rapid systematic review, meta-analysis, and comparison with other inflammatory syndromes. *Lancet Respir Med* 2020; 8(12):1233–1244.
- de Silva R, Dasanayake WMDK, Wickramasinha GD et al. Sensitization to bovine serum albumin as a possible cause of allergic reactions to vaccines. *Vaccine* 2017; 35(11):1494–1500.
- Kucharewicz I, Bodzenta-Łukaszyk A, Buczek W. Experimental asthma in rats. *Pharmacol Rep* 2008; 60(6):783–788.
- McCaskill AC, Hosking CS, Hill DJ. Anaphylaxis following intranasal challenge of mice sensitized with ovalbumin. *Immunology* 1984; 51(4):669–677.
- Ohmori K, Masuda K, Maeda S et al. IgE reactivity to vaccine components in dogs that developed immediate-type allergic reactions after vaccination. *Vet Immunol Immunopathol* 2005; 104(3):249–256.
- Ohmori K, Masuda K, DeBoer DJ et al. Immunoblot analysis for IgE-reactive components of fetal calf serum in dogs that developed allergic reactions after non-rabies vaccination. *Vet Immunol Immunopathol* 2007; 115(1):166–171.
- Jacobsen EA, Zellner KR, Colbert D et al. Eosinophils regulate dendritic cells and Th2 pulmonary immune responses following allergen provocation. *J Immunol* 2011; 187(11):6059–6068.